

**PHYSICAL ASSESSMENT  
INTEGUMENTARY SYSTEM**

---

**Dr. Sahar Adham**

# Equipment

- ✓ Ruler
  - ✓ Lighting
  - ✓ Penlight
  - ✓ Gloves
  - ✓ Magnifying glass
  - ✓ Woods lamp
-

# Nails Assessment

PE Technique :

---

Inspection

Color

Normal : pink

Abnormal: Pale, Bluish

Hygiene: Clean, Wally trimmed

Abnormal: Dirty ,

*Consideration : client work , educational instruction for cleaning*

Shape: Convex ,the angle between the nail bed and the nail is 160 degree

---

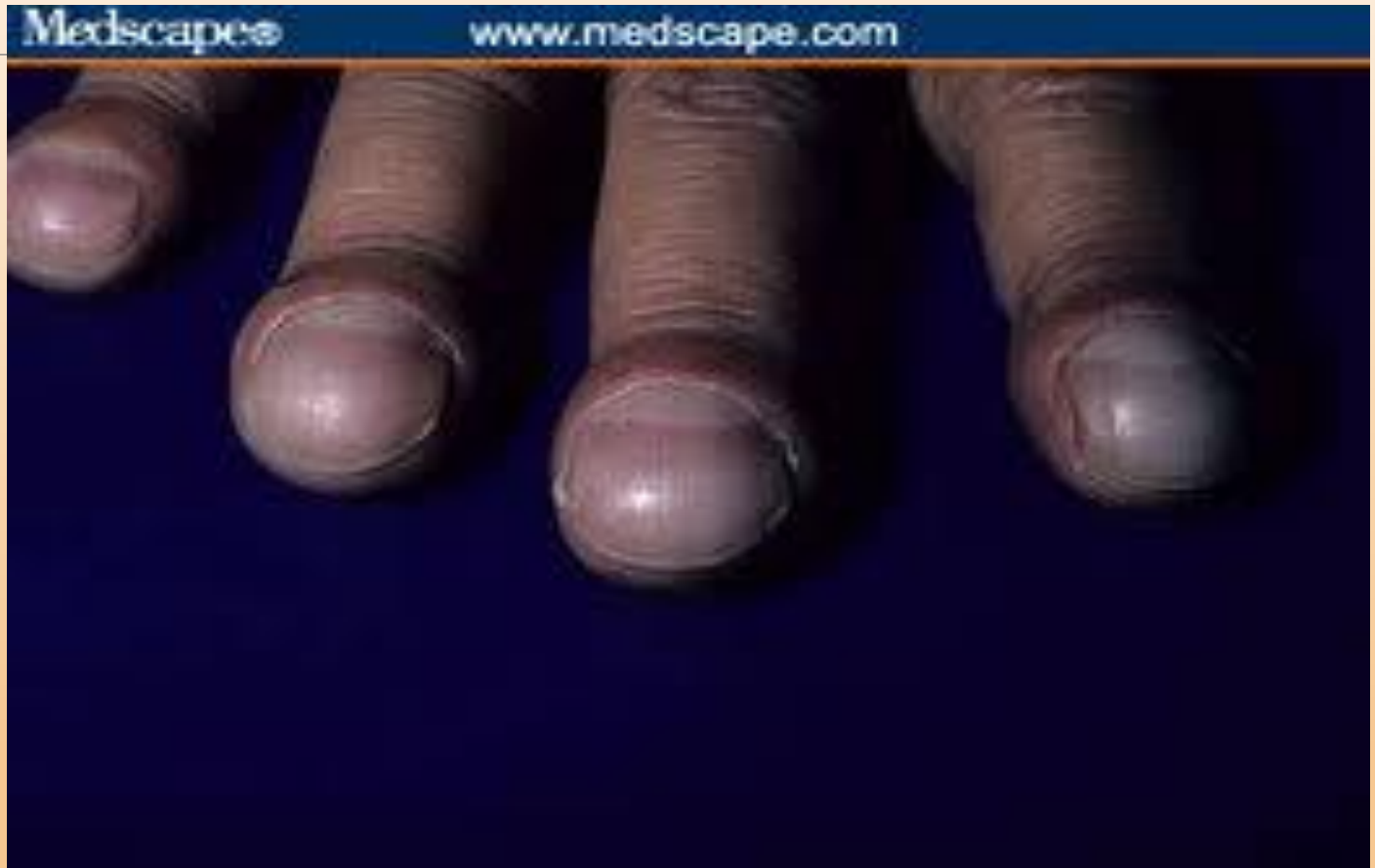Abnormal:

spoon shape : anemia

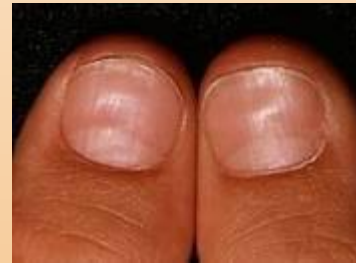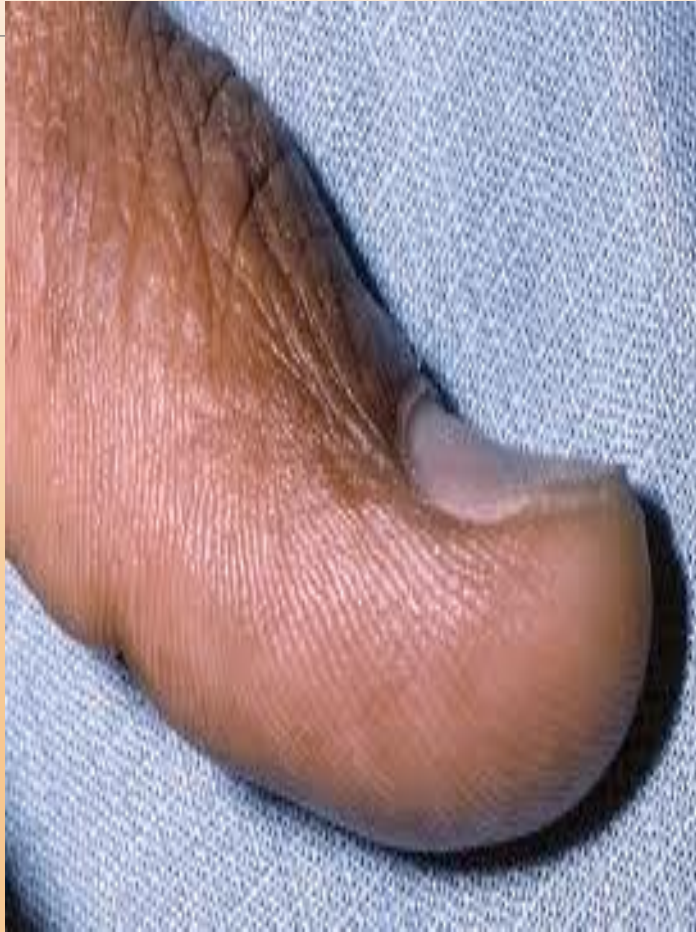clubbing :early clubbing 180 degree , more than 180 degree consider as late clubbing

Beau's line : acute disease

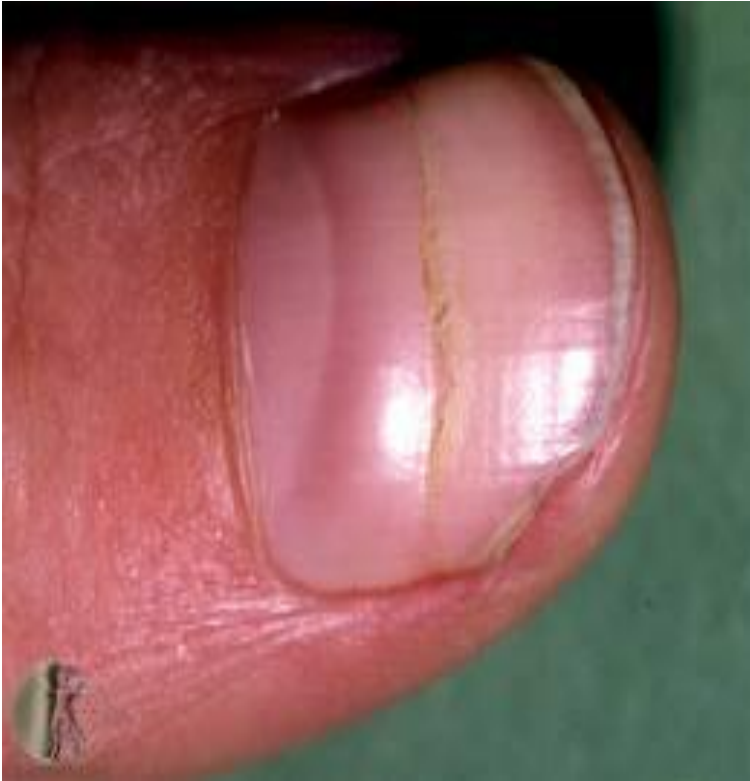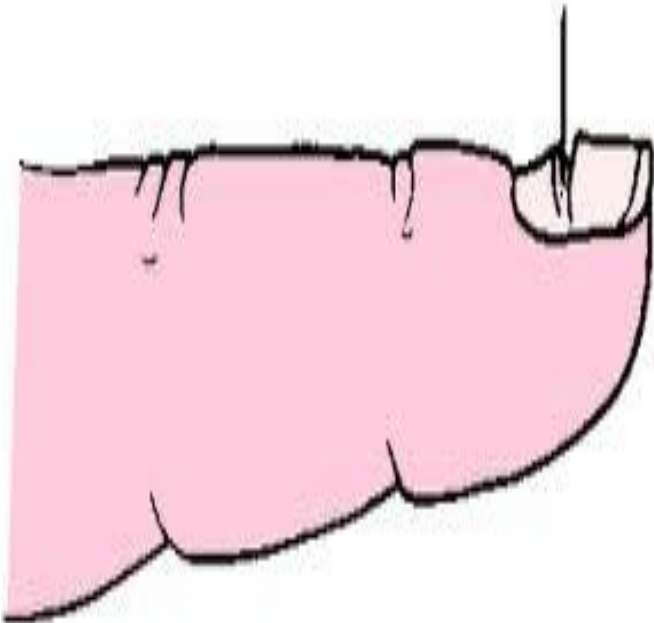
# Later Clubbing



# Spoon Shape (koilonychia)



Beau's line



# PE Palpation

## Texture

---

Normal: smooth & thin

Abnormal: Hard & thick

## Vascularity

Assessed by Blanch test ( refill)  
normal color returned within 2  
second

# Skin Assessment

## PE Technique

---

### Inspection

**Color** : Evenly white to light brown

Abnormal: pale, cyanosis , yellowish & erythema ( local or general)

**Marks and pigmentation** :

Moles ,naive & birth marks normal

Abnormal : changing of Moles ABCDE

## **Pigmentation :**

**petechiae** pin point red flat impalpable  
discoloration of skin

---

**Purpura** : hemorrhage into skin caused  
by decrease platelet ,liver disfunction

**Ecchymosis** : discoloration of skin called  
black and blue mark due to trauma

# Lesion:

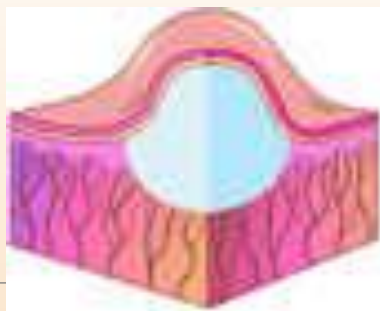
**Macule** : red ,less than 1cm flat as freckle

---

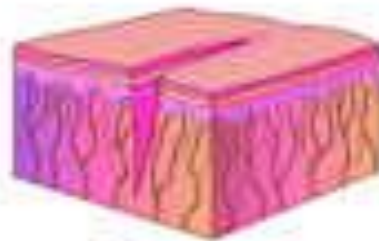**Papule** :Solid elevated less than 0.5 cm such as warts & nevi

**Patch** : red flat more than 1cm 1stage pressure ulcer

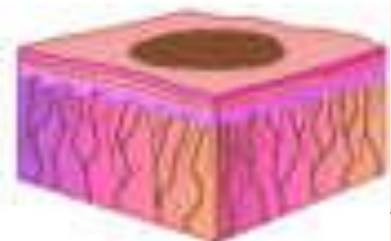
**Nodules** : Solid elevated deep than papule within 0.5-2 cm such as cyst



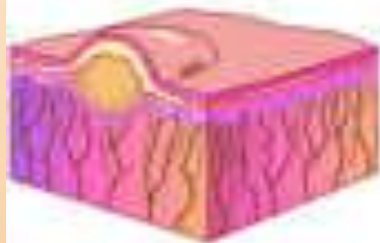Cyst



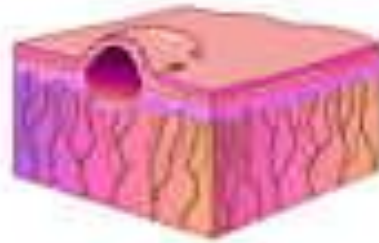
Fissure



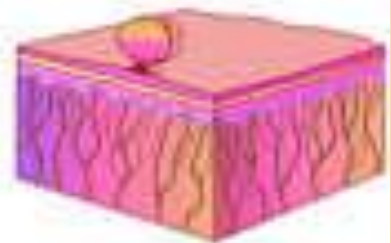
Macule



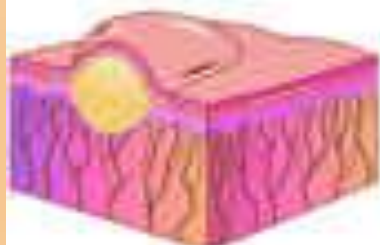Nodule



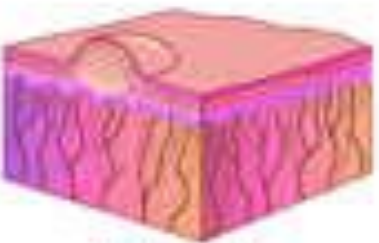
Papule



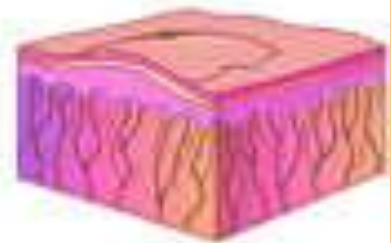
Polyp



Pustule



Vesicle



Wheal

**Vesicle** : Accumulation of fluid in skin elevated , less than 0.5 cm full of serous such as blister

---

**Bullae** : as vesicle but great than 0.5 cm

**Pustule** : such as vesicle less than 0.5 cm put full of pus such as acne

**Wheal** : local edema irregular elevation may be red or pale as insect bite

# Palpation

---

## Temperature

**Texture** : smooth evenly firm

Abnormal : roughness ( occupation ,  
weather & chemical products

**Moisture** : dry some perspiration in  
palm , axially , folded skin area

Abnormal : diaphoresis or clammy

# Mobility and Elasticity ( turgor)

---

Mobility

Elasticity

## Hair Assessment :

Cleanliness : clean ,shiny , free of dandruff and lice's

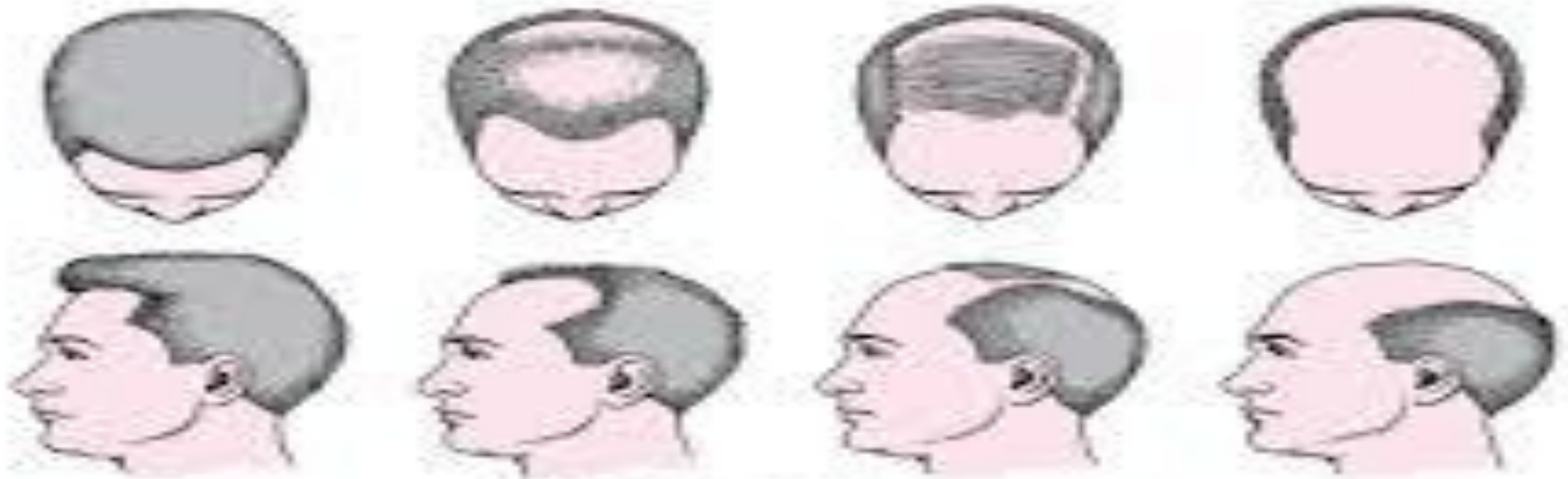
Hair distribution : evenly distributed on the scalp

Color : normal color or chemical color

*Texture : smooth or coarse , oily or dry*

*Scalp : free of lesion and mass*

# Bald



Male-Pattern Baldness



Female-Pattern Baldness

# Alopecia

